

## An unusual distal abdominal migration of a pacemaker pulse generator with a complete epicardial lead fracture

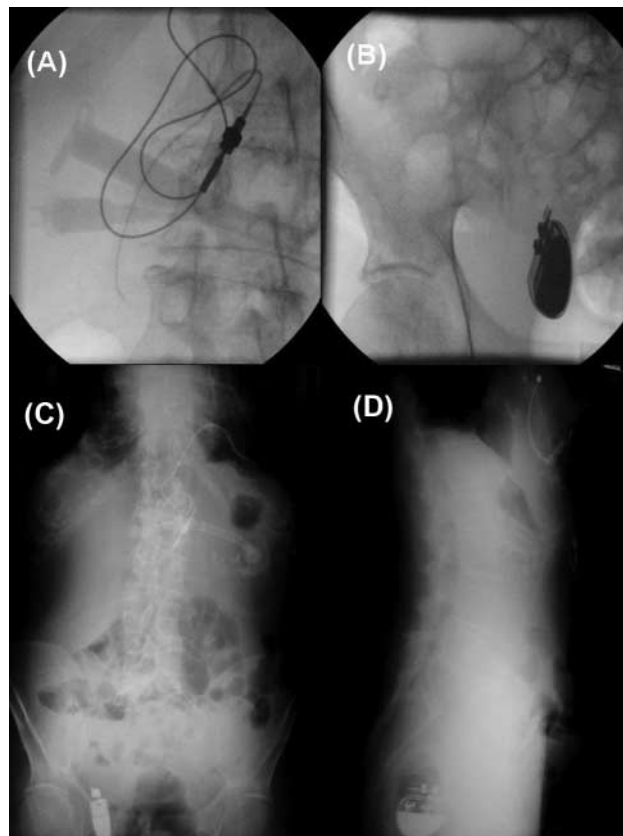
Spyridon Koulouris\*, Socrates Pastromas, and Antonis S. Manolis

First Cardiology Department, Evagelismos Hospital, Kekropos 64, Marousi, 15125 Athens, Greece

\*Corresponding author. Tel: +210 6148740/6944914545; fax: +210 7757571. E-mail address: spyridon.koulouris@gmail.com

A 79-year old man was admitted to our department for exacerbation of dyspnoea at rest. The patient had a rather complicated medical history significant for ischaemic cardiomyopathy, abdominal aortic aneurysm, cerebrovascular disease with a tube feeding in place due to diminished gag reflex, and complete heart block with a permanent epicardial pacemaker implanted for the first time 20 years ago. Of note, since the first implantation the pulse generator was placed in the abdomen under the abdominal rectus muscle. He had his third replacement pulse generator two months ago.

The electrocardiogram revealed pacemaker malfunction with complete loss of capture. A trial to perform an interrogation was unsuccessful as the pacemaker was not able to communicate with the external programming device. Moreover, on physical examination of the upper abdominal area, the pulse generator was not detected in place. An abdominal X-ray revealed a fractured and uncoiled pacemaker lead (Figure 1A) and a retro-peritoneal distal migration of the generator in the right lower abdominal quadrant area (Figure 1B-D). We speculate that the placement of the generator behind the rectus muscle in a weak point of anterior abdominal wall was the main mechanism responsible for this rare complication. Additionally, the atrophic fasciae and muscles of this thin elderly man and the absence of surgical staying stitches might have contributed to the problem. Because of his multiple medical problems and his poor general condition, the patient was not scheduled for surgical removal of the old generator. A new lead was inserted through the right subclavian vein, and a new generator was implanted in the right upper chest. The old fragmented lead was insulated with a silicon cover and the old generator was left in place. A few cases of distal abdominal migration of pacemakers have been reported in the past, mainly in children. This complication has become rare nowadays as the implantation of epicardial pacemaker systems has been mostly abandoned.



**Figure 1** Abdominal x-ray showing the fractured and uncoiled pacemaker lead (A) and the distal migration of the pulse generator in the right lower abdominal quadrant area (B,C,D).