

First Report of Tirofiban-Induced Anemia

(Found in Combination with Severe Thrombocytopenia)

Dimitris Sakellariou, MD
Socrates Pastromas, MD
Spyridon Koulouris, MD
Antonis S. Manolis, MD

We describe the case of a 58-year-old man who developed acute severe anemia and thrombocytopenia after the administration of tirofiban following coronary artery angioplasty. The intravenous administration of IgG immunoglobulin completely resolved both the anemia and the thrombocytopenia. Although thrombocytopenia has been reported as a sequela to the use of tirofiban, there has been no prior report of a link between tirofiban use and anemia. Our successful resolution of both the anemia and the thrombocytopenia with immunoglobulin supports the theory that these severe sequelae of tirofiban are of autoimmune origin. (*Tex Heart Inst J* 2009;36(1):55-7)

Glycoprotein IIb/IIIa receptor antagonists have been routinely used in the treatment of acute coronary syndromes and after percutaneous coronary interventions.¹ These drugs induce thrombocytopenia in approximately 2% to 5% of patients.² Thrombocytopenia is rapid in onset and is thought to be antibody mediated. Abciximab has been associated with a higher incidence of thrombocytopenia than has eptifibatid or tirofiban.³⁻⁵ Severe thrombocytopenia (platelet count, $<50 \times 10^3/\mu\text{L}$) has occurred in 0.2% to 0.5% of patients in clinical trials.⁶ Here, we report a case of combined acute thrombocytopenia and anemia after tirofiban treatment in a patient who underwent elective percutaneous coronary angioplasty.

Case Report

In September 2007, a 58-year-old man was referred to our hospital for elective coronary angiography and angioplasty after a recent acute myocardial infarction (10 days before). He had a history of hyperlipidemia and hypertension, and he was a current smoker (45 pack-years). He had never before experienced cardiac symptoms. The patient had been under treatment with clopidogrel, aspirin, a β -blocker, a statin, and an angiotensin-converting enzyme inhibitor for the past 10 days.

On hospital admission, he had a normal blood count (platelet count, $403 \times 10^9/\text{L}$; hematocrit, 0.41; and hemoglobin, 13.7 g/dL) (Fig. 1). He was sent to the catheterization laboratory after he had received a loading dose of clopidogrel (300 mg) and aspirin (325 mg). Coronary angiography revealed total occlusion of the left circumflex coronary artery and 3 tandem stenoses (80%–90%) in the right coronary artery. Balloon angioplasty was performed after a bolus administration of 10,000 IU of unfractionated heparin, and 3 drug-eluting stents were successfully implanted into the right coronary artery. Immediately after intervention, tirofiban was administered at a dose of 0.2 $\mu\text{g}/[\text{kg}\cdot\text{min}]$ for 30 min, followed by a 24-hour continuous infusion of 0.05 $\mu\text{g}/[\text{kg}\cdot\text{min}]$. Despite his not having any symptoms or signs of bleeding, a blood count taken 4 hours after the intervention revealed severe thrombocytopenia (platelet count, $7 \times 10^9/\text{L}$). A thorough examination of the blood film under microscopy confirmed the finding of thrombocytopenia. Accordingly, tirofiban, clopidogrel, and aspirin were all discontinued, and intravenous IgG immunoglobulin was administered at a dose of 4.5 g/hr. The next morning (20 hours after intervention), the platelet count had increased to $49 \times 10^9/\text{L}$. However, the hematocrit had declined from 0.41 to 0.30 (hemoglobin had fallen from 13.7 g/dL to 9.7 g/dL), in the absence of any obvious clinical signs of hemorrhage. A computed tomographic scan was negative for retroperitoneal hematoma or any other source of internal hemorrhage. Anti-heparin-platelet factor-4 antibodies were negative, and the Coombs reaction was mildly positive. The platelet count increased gradually, along with the hematocrit value. Three days later, the results of both blood tests were back to normal, and the patient was started

Key words: Anemia; platelet aggregation inhibitors; platelet glycoprotein GPIIb/IIIa complex/drug effects; thrombocytopenia; tirofiban

From: 1st Cardiology Department, Evangelismos Hospital, Athens 10676, Greece

Address for reprints: Antonis S. Manolis, MD, 1st Cardiology Department, Evangelismos Hospital, 45-47 Ypsilantou Str., Athens 10676, Greece

E-mail: asm@otenet.gr

© 2009 by the Texas Heart[®] Institute, Houston

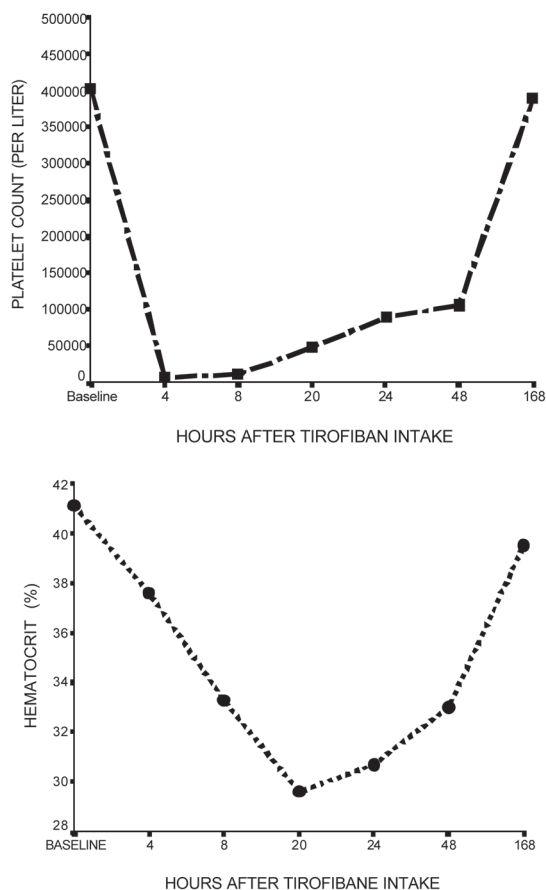


Fig. 1 Time-course of platelet count and hematocrit changes after tirofiban intake.

again on aspirin and clopidogrel. The patient's further hospital course was uneventful, and he was discharged 7 days later with normal hematologic test results (platelet count, $380 \times 10^9/L$; hematocrit, 0.40; and hemoglobin, 13.1 g/dL). Twelve months after discharge, the patient was doing well on clopidogrel and aspirin, and his hematologic results remained absolutely normal.

Discussion

We report a case of severe acute thrombocytopenia and anemia after the administration of tirofiban following a coronary intervention. In accordance with previous studies,⁷ thrombocytopenia had an early onset (4 hours after intervention). Anemia, which to our knowledge has not been described as a side effect of the drug, developed in our patient a few hours later. The possibility of heparin-induced thrombocytopenia due to the administration of unfractionated heparin during the intervention was excluded, because no anti-heparin antibodies were found.

The underlying mechanism of glycoprotein IIb/IIIa antagonist-induced thrombocytopenia seems to be an immune-mediated reaction. Several studies have con-

firmed the presence of circulating antibodies against IIb/IIIa antagonists. It seems that the IIb/IIIa antagonist molecule acts as an antigen itself or induces a conformational change to the receptor, resulting in the exposure of a ligand-induced binding site that either binds directly to the antibody or to the glycoprotein receptor antagonist-antibody complex.^{8,9} Drug-induced antibodies against platelet glycoprotein IIb/IIIa (GPIIb/IIIa) have also been found in patients who developed thrombocytopenia after treatment with the GPIIb/IIIa inhibitors tirofiban and eptifibatide.¹⁰ The fact that the platelet count in our patient rapidly increased after immunoglobulin infusion further supports the hypothesis of immune-mediated thrombocytopenia. To our knowledge, there has been no previous report of a rapid response of coexisting severe anemia (not attributed to bleeding or hemorrhage) to immunoglobulin treatment. Although anemia occurred 20 hours after tirofiban administration, this can be attributed to the longer lifespan of erythrocytes, compared with the lifespan of platelets. Anemia in our patient cannot be attributed to any medication other than tirofiban, which was the only new drug administered a few hours before the development of anemia. The rest of the medications were started at least 10 days before hospital admission and were continued after the resolution of the hematologic abnormalities, without further complication.

In conclusion, the use of tirofiban may induce severe thrombocytopenia and, in some cases, a severe fall in the hematocrit level. Consequently, close monitoring of both platelet count and hematocrit early after the initiation of tirofiban infusion is mandatory and should be continued for 48 hours after the discontinuation of treatment.

References

1. Karvouni E, Katritsis DG, Ioannidis JP. Intravenous glycoprotein IIb/IIIa receptor antagonists reduce mortality after percutaneous coronary interventions. *J Am Coll Cardiol* 2003; 41(1):26-32.
2. Abrams CS, Cines DB. Thrombocytopenia after treatment with platelet glycoprotein IIb/IIIa inhibitors. *Curr Hematol Rep* 2004;3(2):143-7.
3. Dasgupta H, Blankenship JC, Wood GC, Frey CM, Demko SL, Menapace FJ. Thrombocytopenia complicating treatment with intravenous glycoprotein IIb/IIIa receptor inhibitors: a pooled analysis. *Am Heart J* 2000;140(2):206-11.
4. Merlini PA, Rossi M, Menozzi A, Buratti S, Brennan DM, Moliterno DJ, et al. Thrombocytopenia caused by abciximab or tirofiban and its association with clinical outcome in patients undergoing coronary stenting. *Circulation* 2004;109(18):2203-6.
5. Tchong JE. Clinical challenges of platelet glycoprotein IIb/IIIa receptor inhibitor therapy: bleeding, reversal, thrombocytopenia, and retreatment. *Am Heart J* 2000;139(2 Pt 2):S38-45.
6. Inhibition of the platelet glycoprotein IIb/IIIa receptor with tirofiban in unstable angina and non-Q-wave myocardial infarction. *Platelet Receptor Inhibition in Ischemic Syndrome Management in Patients Limited by Unstable Signs and*

- Symptoms (PRISM-PLUS) Study Investigators [published erratum appears in N Engl J Med 1998;339(6):415]. N Engl J Med 1998;338(21):1488-97.
7. Huxtable LM, Tafreshi MJ, Rakkar AN. Frequency and management of thrombocytopenia with the glycoprotein IIb/IIIa receptor antagonists. Am J Cardiol 2006;97(3):426-9.
 8. Aster RH. Drug-induced immune thrombocytopenia: an overview of pathogenesis. Semin Hematol 1999;36(1 Suppl 1):2-6.
 9. Madan M, Berkowitz SD. Understanding thrombocytopenia and antigenicity with glycoprotein IIb-IIIa inhibitors. Am Heart J 1999;138(4 Pt 2):317-26.
 10. Bougie DW, Wilker PR, Wuitschick ED, Curtis BR, Malik M, Levine S, et al. Acute thrombocytopenia after treatment with tirofiban or eptifibatid is associated with antibodies specific for ligand-occupied GPIIb/IIIa. Blood 2002;100(6):2071-6.