

CARDIOLOGY UPDATE 2006

ECG Changes and Voltage Attenuation in Congestive Heart Failure

John E. Madias, MD

*Mount Sinai School of Medicine of the
New York University and the Division
of Cardiology, Elmhurst Hospital
Center, New York, NY*

KEY WORDS: *ECG; congestive heart
failure; peripheral edema; body volume
conductor; electrical impedance;
diuresis; implantable cardioverter
defibrillator; cardiac resynchronization
therapy; QT intervals*

ABSTRACT

The electrocardiogram (ECG) is invaluable in providing diagnosis, prognosis, and information for decision making in the management of patients with congestive heart failure (CHF). In addition to the traditional applications of the ECG, which are of importance in the management of patients with CHF, and include indeed the bulk of ECG derived information, a recently described association of peripheral edema with attenuated ECG voltage, provides an expanded dimension in diagnostics. These attenuations result in decreased amplitude of QRS complexes, P-waves, and shortened duration of QRS complexes and QT intervals, with significant diagnostic implications. Alleviation of peripheral edema in response to diuresis in patients with CHF reverses all above alterations.

The electrocardiogram (ECG) has many established applications useful for the diagnosis, management, and follow-up of patients with congestive heart failure (CHF). Since CHF can be the outcome of many pathophysiological derangements, the ECG of such patients may show a large range of abnormalities. Occasionally patients with CHF may have a normal ECG, or merely show sinus tachycardia without any other abnormalities. More commonly however, the ECG of patients with CHF may reveal left ventricular hypertrophy (LVH), all types of atrial and ventricular arrhythmias, atrio-ventricular and intra-ventricular conduction blocks, evidence of myocardial ischemia and/or myocardial infarction, right ventricular hypertrophy, and left and right atrial abnormalities; indeed it is safe to state that almost any ECG tracing contained in a comprehensive electrocardiography text [1] could be seen in a patient with CHF! Classic examples of ECG abnormalities associated with CHF are LVH, evidence for left atrial abnormality, and atrial fibrillation. Along this line of thought one may conclude that there are no strictly speaking specific ECG features of CHF, since any ECG seen in patients with other clinicopathological entities, can also be seen in patients with CHF.

Address for correspondence:

Dr. John E. Madias

Professor of Medicine (Cardiology)

Division of Cardiology

Elmhurst Hospital Center

79-01 Broadway, Elmhurst,

NY 11373, USA

Tel.: (718) 334-5005; FAX: (718) 334-5990

e-mail: madiasj@nychhc.org

ECG PATTERNS IN CHF

An attempt has been made over the years to connect certain ECG appearances to CHF, particularly severe CHF in patients with ischemic and nonischemic cardiomyopathy. Such patterns include left bundle branch block (LBBB), left fascicular blocks, particularly left posterior fascicular block [2], intraventricular conduction de-

lays, low amplitude QRS complexes due to multiple previous myocardial infarctions, ventricular aneurysms [3], and a triad characterized by low voltage in the limb leads, high voltage in the precordial leads, and a R/S ratio <1.0 in lead V4 [4]. In addition, since many patients with CHF receive implantable cardioverter/defibrillators (ICDs), pacemakers, and cardiac resynchronization systems, a paced ECG pattern (usually LBBB-like in appearance) is often encountered. Recently the so called “strain pattern” of ST-segment depression and T-wave inversion in patients with ECG evidence of LVH was reported to be predictive of increased risk of developing CHF, and of dying as a result of CHF, even with aggressive blood pressure lowering [5]. However, the above list is not all-inclusive or comprehensive, and if one scrutinizes the literature, many more ECG entities may be found that satisfy the role of a “somewhat specific for”, or “characteristic of”, or “frequently encountered in” patients with CHF, ECG pattern.

ECG VOLTAGE ATTENUATION IN CHF IN PRESENCE OF PERIPHERAL EDEMA

Recently work has been published showing an association of attenuation of the amplitude of QRS complexes [6], and P-waves [7], shortening of the QRS duration [8], and QTc intervals [9], with peripheral edema (PEED), due to a variety of clinical conditions. Such ECG changes in the presence of PEED may “camouflage” the diagnostic evidence of ECG LVH/dilatation [10], and of left and right atrial abnormalities [11] which were present prior to the development of PEED. These PEED-mediated limitations in the assessment of the QRS duration and QTc intervals are encountered with both manual and automated measurement methods. Since the QRS duration is employed as a severity index in the evaluation of patients for ICD implantation or cardiac resynchronization therapy [12-14], such artificial shortening of the QRS duration compromises the diagnostic role of this ECG parameter. Also the QTc is artificially shortened with attenuation of ECG voltage in patients with PEED, and thus QTc may lose its reproducibility, or its diagnostic and prognostic value. It is speculated that the performance of both the QRS duration and the QTc interval as indices of severity of pathology, or in the follow-up of patients with CHF and PEED in previous studies might have been compromised by the perturbations in the edematous state of the patients, and thus it deserves to be looked at a new, in the context of this insight [15]. It has also been observed that such apparent shortening of the QRS duration may artificially ameliorate complete bundle branch blocks and intraventricular conduction delays, converting them to ECGs showing incomplete bundle branch blocks or intraventricular conduction abnormalities, or even normal intraventricular conduction [16]. It should be understood that this shortening of QRS duration, and QTc intervals is apparent, as

assessed by the manual or electronically based measurements; thus these alterations are not cardiac, or electrophysiologically mediated, and the shortening results from failure of a portion of the onset and offset of QRS and QTc intervals to be accounted for, due to their reduced amplitude as a result of the overall ECG curve voltage attenuation, rendering them unmeasurable and indistinguishable from “noise” [8,9]. The above noted changes in the ECG in the presence of PEED, and their reversion to normal with alleviation of fluid overload correlate well with changes in weight and can be employed in the diagnosis and follow-up of patients with CHF [17-20].

MECHANISM OF ECG ATTENUATION

The mechanism of the attenuation associated with PEED appears to be extracardiac in nature, and due to a short-circuiting effect on the electrical voltage generated at the epicardial surface, exerted by the passive volume conductor containing the heart; the short-circuiting effect in turn is due to the fluid-based reduction of the electrical impedance of the volume conductor (low resistivity of the excess fluid). The above-described attenuations of the entire ECG curve affect patients with CHF when they go through phases of poor compensation, accumulating in the process excess fluid, and gaining weight. Conversely when patients with CHF respond favorably to medical management with effective diuresis, all the above changes are reversed [17-21].

ATTENUATION REVERSAL AND CLINICAL CORRELATES

In general, ECG diagnostics relying on amplitude and duration measurements are expected to be interfered with in patients with PEED. In contrast, when fluid overload is alleviated, the amplitudes of QRS complexes and P-waves, the QRSd, and the QTc intervals are augmented, depending on the extent of reduction of the PEED. This return to normalcy or improvement is also reproducibly experienced after hemodialysis [7,9,22] by and may be seen in patients with CHF and PEED who have end-stage renal failure and undergo this procedure.

Attenuation with PEED in patients with CHF correlates well with weight gain from fluid overload, and this association can be put to work in the diagnosis and follow-up of such patients. Perusal of serial ECGs of patients with CHF and PEED indicates that the amplitude of QRS complexes are at its lowest when the patients show the highest weight and the most conspicuous PEED on physical examination. In contrast, the amplitude of QRS complexes is at its highest when the patients' weight is at its lowest, and the PEED has responded favorably to diuresis [17-21] (Figure 1). The attenuation of

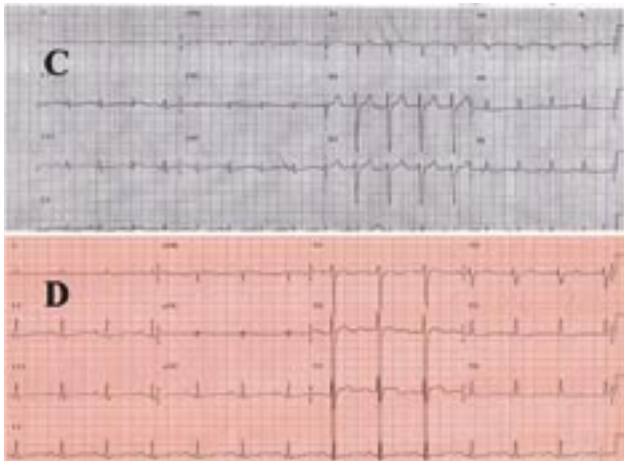


FIGURE 1. Standard ECGs obtained from a 54-year-old man with congestive heart failure and peripheral edema on admission (C), when he weighed 85.5 Kg, and prior to discharge 15 days later (D) when he weighed 63.6 Kg. This loss of 21.9 Kg (25% decrease) was associated with an increase of the sums of QRS complexes from 99 mm on admission to 182.5 mm at discharge (84% increase) (Reproduced with permission of the journal “Congestive Heart Failure”, Ref #20).

ECG voltage/PEED concept can be utilized in clinical practice and research, and can be employed either via a quantitative treatment of the 12-lead ECG [6-11], or by “eye-balling” the amplitude of leads I and II, at the patient’s bedside, in the clinic or the office, summing the estimates of amplitude from these 2 leads and comparing serially such values with gain or loss of patient’s weight or clinical evidence of PEED [23].

CONCLUSION

In conclusion, this new insight about the link between PEED and attenuation of ECG voltage can be employed in manifold ways in the diagnosis and management of patients with CHF. Obviously measurements from a single ECG are not adequate for these purposes, but measurements from serial ECGs of the parameters described above are very useful, and provide the opportunity to evaluate patients with CHF and PEED, via an inexpensive modality ubiquitously present, obtainable at any time, and in any environment, regardless of its sophistication, –the 12-lead ECG.

REFERENCES

1. Comprehensive Electrocardiology. Theory and Practice in Health and Disease, Macfarlane PW and Veitch Lawrie TD, Editors, First Edition, 1989, Pergamon Press, New York.
2. Childers R, Lupovich S, Sochanski M, Konarzewska H. Left bundle branch block and right axis deviation: a report of 36

- cases. *J Electrocardiol* 2000; 33 Suppl:93-102.
3. Madias JE, Ashtiani R, Agarwal H, Narayan VK, Win M, Sinha A. Diagnosis of ventricular aneurysm and other severe segmental left ventricular dysfunction consequent to a myocardial infarction in the presence of right bundle branch block: ECG correlates of a positive diagnosis made via echocardiography and/or contrast ventriculography. *Ann Noninvasive Electrocardiol* 2005; 10:53-9.
4. Goldberger AL. A specific ECG triad associated with congestive heart failure. *Pacing Clin Electrophysiol* 1982; 5:593-9.
5. Okin PM, Devereux RB, Nieminen MS, et al. Electrocardiographic strain pattern and prediction of new-onset congestive heart failure in hypertensive patients. The Losartan Intervention for Endpoint Reduction in Hypertension (LIFE) Study. *Circulation* 2006; 113:67-73.
6. Madias JE, Bazaz R, Agarwal H, Win M, et al. Anasarca-mediated attenuation of the amplitude of electrocardiogram complexes: a description of a heretofore unrecognized phenomenon. *J Am Coll Cardiol* 2001; 38:756-64.
7. Madias JE. P waves in patients with changing edematous states: implications on interpreting repeat P wave measurements in patients developing anasarca or undergoing hemodialysis. *Pacing Clin Electrophysiol* 2004; 27:749-56.
8. Madias JE. Significance of shortening of the mean QRS duration of the standard electrocardiogram in patients developing peripheral edema. *Am J Cardiol* 2002; 89:1444-6.
9. Madias JE. QTc interval in patients with changing edematous states: implications on interpreting repeat QTc interval measurements in patients with anasarca of varying etiology and those undergoing hemodialysis. *Pacing Clin Electrophysiol* 2005; 28:54-61.
10. Madias JE. Concealment of electrocardiographically based diagnosis of left ventricular hypertrophy by anasarca. *Am J Hypertens* 2004; 17:897-903.
11. Madias JE. Masking of the diagnoses of P-pulmonale, P-mitral, and biatrial abnormality by peripheral edema: Clinical implications for patients with heart failure. *Congestive Heart Failure* 2006; 12:20-24.
12. Zimetbaum PJ, Buxton AE, Batsford W, et al. Electrocardiographic predictors of arrhythmic death and total mortality in the multicenter unsustained tachycardia trial. *Circulation* 2004; 110:766-769.
13. Shamim W, Yousufuddin M, Cicoria M, et al. Incremental changes in QRS duration in serial ECGs over time identify high risk elderly patients with heart failure. *Heart* 2002; 88: 47-51.
14. Molhoek SG, VAN Erven L, Bootsma M, et al. QRS duration and shortening to predict clinical response to cardiac resynchronization therapy in patients with end-stage heart failure. *Pacing Clin Electrophysiol* 2004; 27:308-313.
15. Madias JE. The impact of changing oedematous states on the QRS duration: implications for cardiac resynchronization therapy and implantable cardioverter/defibrillator implantation. *Europace* 2005; 7:158-64.11.
16. Madias JE. Apparent amelioration of bundle branch blocks and intraventricular conduction delays mediated by anasarca.

- J Electrocardiol* 2005; 38:160-5.
17. Madias JE, Agarwal H, Win M, Medepalli L. Effect of weight loss in congestive heart failure from idiopathic dilated cardiomyopathy on electrocardiographic QRS voltage. *Am J Cardiol* 2002; 89:86-88.
 18. Madias JE, Attanti S, Narayan V. Relationship among electrocardiographic potential amplitude, weight, and resistance/reactance/impedance in a patient with peripheral edema treated for congestive heart failure. *J Electrocardiol* 2003; 36:167-171.
 19. Madias JE, Song J, White CM, Kalus JS, Kluger J. Response of the ECG to short-term diuresis in patients with heart failure. *Ann Noninvasive Electrocardiol* 2005; 10:288-96.
 20. Madias JE. Standard electrocardiographic and signal-averaged electrocardiographic changes in congestive heart failure. *Congest Heart Fail* 2005; 11:266-71.
 21. Madias JE. On the mechanism of augmentation of electrocardiogram QRS complexes in patients with congestive heart failure responding to diuresis. *J Electrocardiol* 2005; 38:54-7.
 22. Madias JE, Narayan V. Augmentation of the amplitude of electrocardiographic QRS complexes immediately after hemodialysis: a study of 26 hemodialysis sessions of a single patient, aided by measurements of resistance, reactance, and impedance. *J Electrocardiol* 2003; 36:263-71.
 23. Madias JE. A comparison of 2-lead, 6-lead, and 12-lead ECGs in patients with changing edematous states: implications for the employment of quantitative electrocardiography in research and clinical applications. *Chest* 2003; 124:2057-63.