

## Closure of Atrial Septal Defect and Patent Foramen Ovale, the Simple Way

Bernhard Meier, MD

*Swiss Cardiovascular Center Bern,  
University Hospital Bern, Bern,  
Switzerland*

**KEY WORDS:** *atrial septal defect;  
patent foramen ovale; device closure;  
interatrial shunt*

### ABSTRACT

Catheter based closure of atrial septal defects was first described in 1974 but has only been used widely since the nineties. In 1992 the focus turned to closure of the patent foramen ovale which today is the most common atrial shunt closure. While the majority of centers advocate use of transesophageal or intracardiac echocardiographic guidance during implantation, fluoroscopy guided implantation is feasible, faster, cheaper, and more patient-friendly. Closure of a patent foramen ovale with an Amplatzer occluder (currently the preferred device) may take as little as 10 minutes with the possibility to return to full physical activity a couple of hours later. Complications are exceedingly rare (<1%). They include (about in the order of frequency) inguinal access problems, thrombus on the device, device embolization, cardiac perforation, erosion of the atrial wall by the device, or infection of the device. So far there are no reports of late complications although atrial fibrillation is one to be looked out for.


### INTRODUCTION

A patent foramen ovale (PFO) is present in all babies at birth and about 30% of teenagers. The prevalence decreases to about 20% in octogenarians [1]. While a PFO is not considered a congenital heart defect, the atrial septal defect (ASD) is. Its most common form, the ASD II (secundum, located in or around the fossa ovalis and not involving atrial inflow structures or heart valves) constitutes the most common congenital heart defect together with the ventricular septal defect (VSD). It is present in about 0.1 % of people and ranges from minute to huge (e.g., 4 cm). It may be multiple (Swiss cheese variety). An ASD secundum may lead to significant volume overload, resulting in enlargement of all heart chambers, save the left ventricle. Atrial fibrillation is its most common and feared complication occurring typically after the age of 40 years and being the number one reason (before heart failure) for mortality. Surgical closure of an ASD in adults failed to reduce the incidence of atrial fibrillation over the subsequent 30 years [2].

The first report of successful closure of an atrial septal defect dates back to 1974 [3] preceding coronary angioplasty by more than 3 years. The introduction of the Rashkind atrial septal occluder in the eighties rekindled the interest in interatrial shunt closure that had lain dormant for 10 years, but catheter based ASD closure became commonplace only in the nineties with the introduction of self-centering devices, particularly the Amplatzer occluder (Figure 1). In 1992 a first report on PFO closure to prevent paradoxical stroke launched a new era [4]. While ASD closure will remain a fairly rare procedure, PFO closure has the potential to become the most

*Address for correspondence:*

Bernhard Meier, MD  
Professor and Chairman of Cardiology  
Swiss Cardiovascular Center Bern  
University Hospital Bern  
3010 Bern, Switzerland  
Tel: +41 31 632 30 77  
Fax: +41 31 382 10 69  
E-mail: bernhard.meier@insel.ch



**FIGURE 1.** Dedicated atrial septal defect (ASD) closure devices. The self-centering during and after implantation is attempted by strings in the StarFlex device (NMT Medical, Boston, Massachusetts, U.S.A.), by flexible wires in the Sideris COD device (Sideris, Athens, Greece), by a waist diameter commensurate with the defect in the Amplatzer Septal Occluder (AGA, Minneapolis, Minnesota, U.S.A.), and by a foam ring in the Intrasept ASD closure device (Cardia Inc. Burnsville, Minneapolis, U.S.A.). The only device used widely is the Amplatzer Septal Occluder.

common procedure in interventional cardiology. Already, it accounts for about 10% of the interventional activity in some pioneering centers.

---

**INDICATIONS**

---

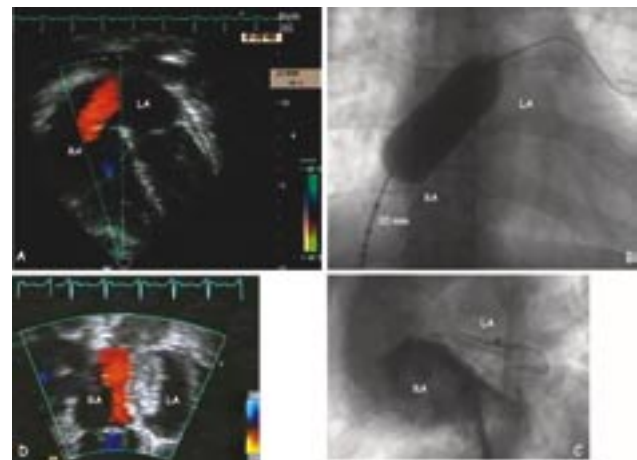
The smaller the ASD, the easier is catheter based closure with the PFO as the extreme example. Hence, it can be argued that all ASDs should be closed. The large ones because of their hemodynamic importance, the small ones and the PFOs because of their potential for paradoxical embolism and acknowledging their lack of intricacy for closing.

---

**TECHNIQUE OF CLOSURE  
INTERATRIAL SHUNTS WITHOUT  
ECHOCARDIOGRAPHIC GUIDANCE**

---

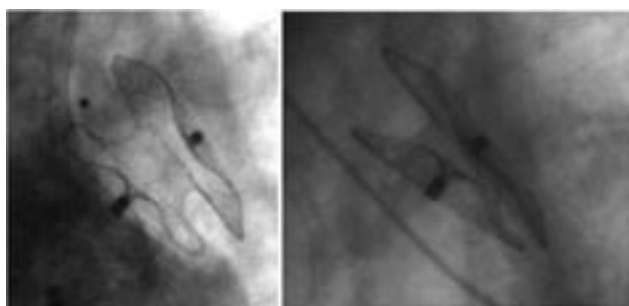
A transesophageal echocardiography is the best base for the indication of closure of any interatrial shunt. With the Amplatzer ASD occluder (Figure 2) it is not necessary to measure the rims. The device will conform to virtually any anatomy, provided the defect is not too large (>40 mm) and an adequately sized device is selected. It is recommended to



**FIGURE 2.** A. Transthoracic echocardiography in a 41-year-old woman showing an ASD II projected in the view used for fluoroscopy during catheter based device closure. The left to right shunt is made visible by Doppler color flow. B. Measuring balloon across the defect yielding a diameter of 20 mm. The top 2 calibration markers are separated by 10 mm. C. Control hand injection of a small amount of contrast medium through the introducer sheath (9 French) after implantation of a 30 mm Amplatzer Occluder. The position can be ascertained without need for echocardiography. D. Corresponding transthoracic echocardiographic view of the device 1 day later showing no residual shunt. LA = left atrium; RA = right atrium.

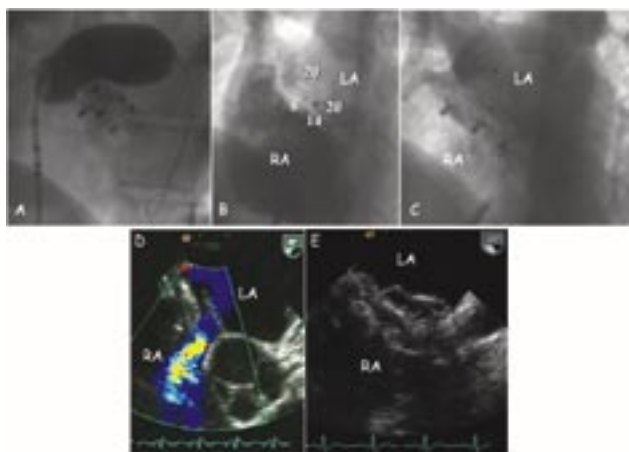
perform a stretched defect measurement with a sizing balloon (compliant latex balloon with sizing markers) (Figure 2). There is a small risk of enlarging the ASD by tearing a possibly very thin portion of the septum primum with the measuring balloon. However, this may avoid undersizing of the device, which could be unstable if implanted commensurate to an echocardiographically measured ASD without paying attention to the stability of the surrounding rim in the region of the septum primum. If the measuring balloon shows a clear waist and remains in stable position straddling the defect, an Amplatzer septal occluder about 20% larger than the measured diameter should be selected. If the balloon cannot be stabilized in the ASD, this indicates instability of part of the septal wall and mandates oversizing of the device compared with the balloon measurement by 30%-50%.

Oversizing of the device has been advised against by a report analyzing the potential causes of the dreaded, albeit rare, device erosion due to friction of the device against the external atrial wall in contact with the pulsating aorta [5]. A contrary theory is that a somewhat oversized Amplatzer occluder will have rounder edges at least during the initial phase (Figure 2 C) and therefore should be less erosion-prone. During follow-up even generously sized Amplatzer occluders will flatten down (Figure 3).



**FIGURE 3.** Flattening of a slightly oversized Amplatzer occluder over time. Left panel: Situation after implantation. A hand injection of contrast medium into the right atrium depicts the correct position equally well as an intraprocedural echocardiogram. The neck of the intentionally oversized Amplatzer Occluder is slightly constricted, keeping the disks in a somewhat rounded shape. Right panel: 18 months later the device has flattened down and the neck has fully expanded.

If the intervention was based on a state-of-the-art transesophageal echocardiography, it is unlikely to miss additional ASDs by not using echocardiography during the intervention. Figure 4 demonstrates the case of a 27-year-old woman who

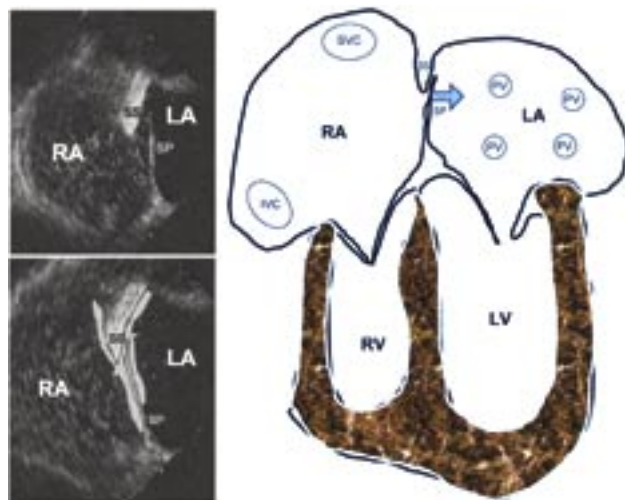


**FIGURE 4.** Quadruple ASD closure in a 27-year-old woman. A. Balloon measuring of a fourth large ASD missed during two previous interventions (second one done with transesophageal echocardiographic guidance). B. 4 Amplatzer septal occluders nestled in the interatrial septum. The right atrium is opacified by contrast medium injection into the right atrium (RA). C. Levophase of the contrast medium injection into the RA with opacification of the left atrium (LA). D. Transesophageal echocardiogram before the last device implantation showing significant left-to-right shunt by color Doppler next to the aorta. E. Transesophageal echocardiographic follow-up at 6 months showing good position of all 4 devices. There was no residual shunt.

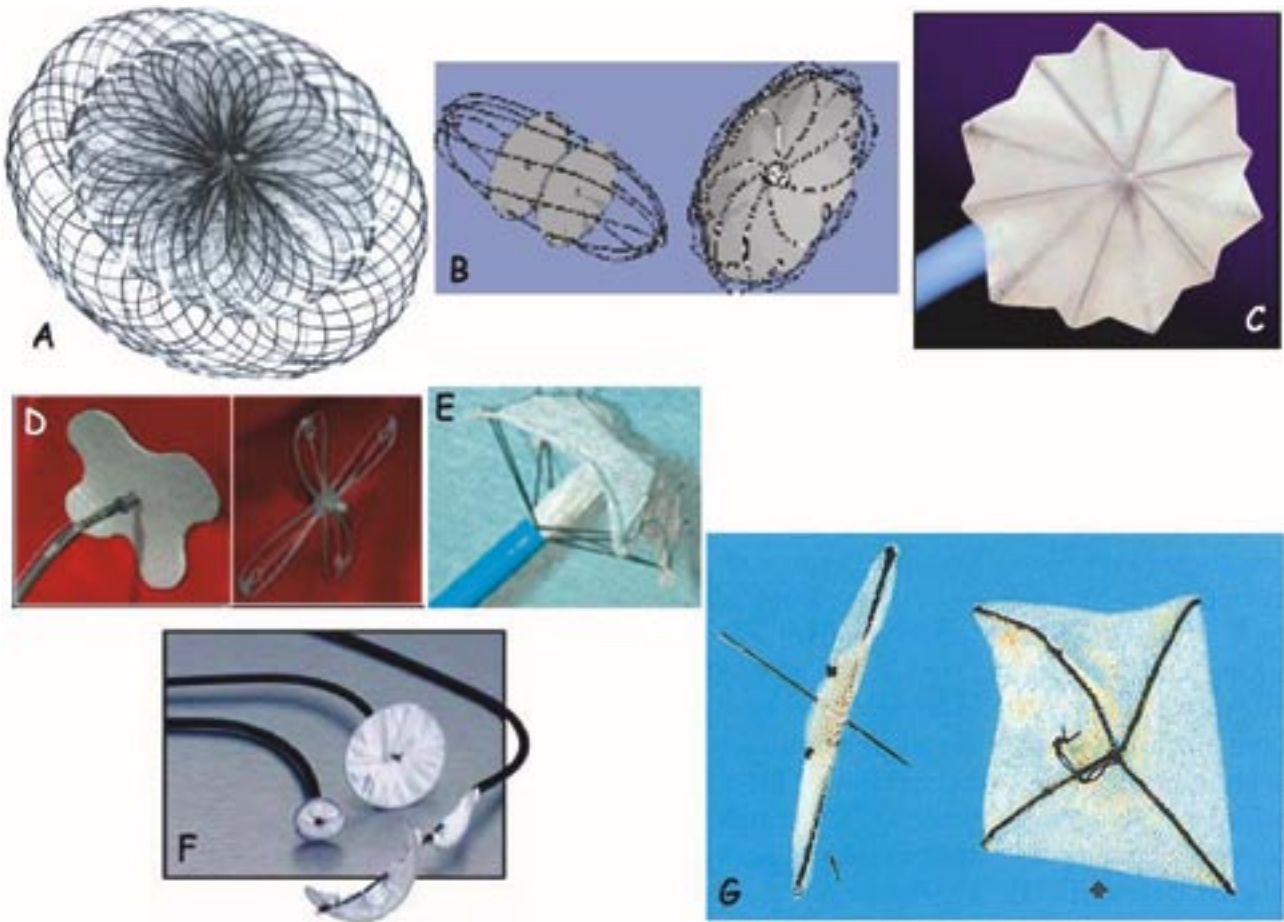
wound up with 4 devices after 3 additional ASDs had been missed during closure of a presumed single ASD (report of a pre-intervention transesophageal echocardiogram) at the first intervention. During the second intervention, two ASDs were closed using transesophageal echocardiography. During follow-up, it turned out that an additional sizable ASD had been missed which was closed in a final third intervention, again without echocardiographic guidance. The septum was completely closed at follow-up.

The technique for PFO closure is analogous but even more simple. Figure 5 explains some salient features. Of the large variety of devices available for that purpose (Figure 6), only 3 have collected significant clinical experience (Amplatzer PFO occluders, PFOStar/TransSeptal devices, and the CardioSeal/StarFlex devices).

The key feature for correctly placing an Amplatzer PFO occluder (or any occluder for that matter) without echocardiographic guidance is an ideal angiographic projection combined with injection of contrast medium (performed by hand through the introducer sheath) where pertinent (Figure 7). If the device fails to straddle the septum secundum (negative Pacman sign), this will not necessary lead to embolization for the reasons explained in figure 8 but it will increase the risk



**FIGURE 5.** Left panel: Transesophageal echocardiography projected in analogy to the usual fluoroscopic aspect depicted graphically in the right panel. The PFO is a gap between the thick muscular septum secundum (SS) and the flap like thin septum primum (SP) which can move away from the SS towards the left atrium (arrow) (LA). The right atrium (RA) is filled with echocardiographic contrast bubbles which find access to the LA (top) after a sustained Valsalva maneuver while the blood is rushing back to the RA with the LA still underfilled. This mechanism is prevented by device closure (bottom). IVC = inferior vena cava; LV = left ventricle; PV = pulmonary vein; RV = right ventricle; SVC = superior vena cava.



**FIGURE 6.** Currently available devices for PFO closure in order of their user-friendliness and performance. A. Amplatzer PFO Occluder device, available in 5 sizes all with a thin, flexible and extendible neck: 25 mm (right disk 25 mm, left disk 18 mm, standard device); 35 mm (right disk 35 mm, left disk 22 mm); 18 mm (both disks 18 mm); Cribriform 25 mm (both disks 25 mm); Cribriform 35 mm (both disks 35 mm), (AGA, Minneapolis, Minnesota, U.S.A.), B. Solysafe (Carag, Baar, Switzerland), C. TransSeptal device (Cardia Inc. Burnsville, Minneapolis, U.S.A.), D. Premere device (Velocimed, Maple Grove, Minneapolis, U.S.A.), E. StarFlex device (formerly CardioSeal) (NMT Medical, Boston, Massachusetts, U.S.A.), F. Helix Septal Occluder device (Gore Newark, Delaware, U.S.A.), G. Sideris Buttoned Occluder device (Sideris, Athens, Greece).

for a residual shunt.

---

**CONCLUSION**

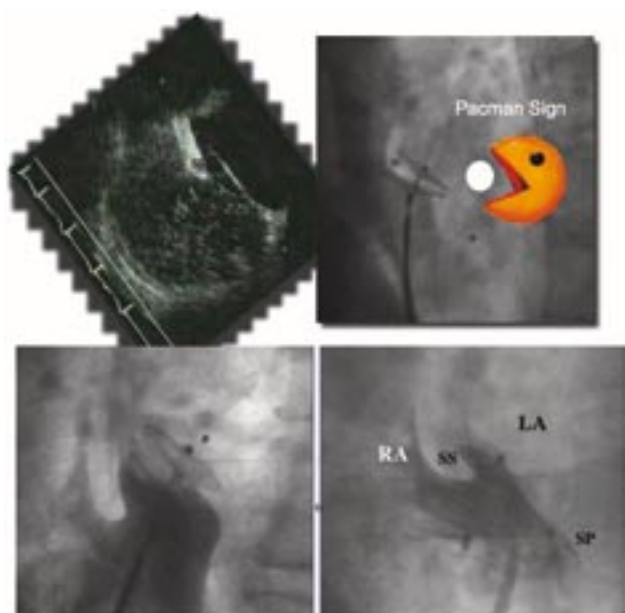
---

The advantages and disadvantages of using echocardiographic guidance for atrial shunt closure are summarized in Table 1. While a number of centers have already abandoned echocardiography during PFO closure for the simplicity of this procedure and its high number of cases mandating a frugal approach, echocardiographic guidance is still deemed mandatory for ASD closure in general. My experience with ASD closures with and without echocardiographic assistance proves that judicious and intelligent exploitation of fluoros-

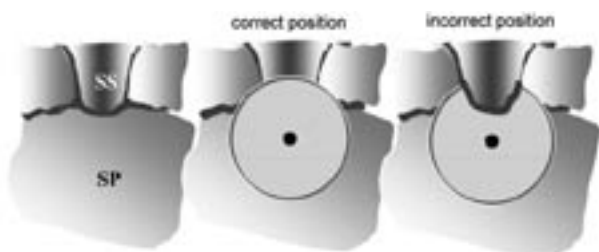
copy obviates the need for simultaneous echocardiography during any Amplatzer device implantation. Other devices are more cumbersome to implant but still do not mandate echocardiography either.

Hence, fluoroscopically guided closure of PFOs and ASDs is not only feasible but safe and equally effective as echocardiographically guided techniques. It affords considerable economical and comfort advantages. Table 2 recapitulates the important steps of the technique.

Interventional cardiologists embarking on interatrial shunt closure should start with the PFO using the 35 mm Amplatzer PFO Occluder for the initial cases. This is by far the easiest-to-use device with a good record of permanent occlusion. Once they feel comfortable with PFO closures using the standard



**FIGURE 7.** Pacman sign for correct placement of PFO occluders. The Pacman sign consists of a V-shaped configuration of the left and right atrial disks, respectively, when viewed in a projection (usually left anterior oblique view with cranial tilt) showing the device in perfect profile. The septum secundum (SS) being thick and muscular separates the left cranial part of the device much more than the septum primum (SP) being thin and flexible. The top panel shows the anatomy by transesophageal echocardiography (left) and by angiography (right) using the arcade figure Pacman as analogy. The bottom panel shows an incorrect placement (left, 18 mm Amplatzer PFO Occluder) where the septum secundum is not between the two disks and the correct placement of a 25 mm Amplatzer PFO Occluder in the same patient (right). LA = left atrial; RA = right atrium.



**FIGURE 8.** Schematic explanation (view from the right atrium) for the Pacman sign and the situation if it is not honored. The left panel shows the anatomy with a small cranial sector where the septum secundum is thick. The middle panel shows the correct position of the right atrial disk. The right panel shows the incorrect position where the thick part of the septum secundum is not between the disks but to the right of the right atrial disk. It is apparent that the device will not embolize in spite of the incorrect position because the prolapse of the right atrial disk into the left atrium encompasses only a small sector of the circumference. SS = septum secundum; SP = septum primum.

**TABLE 1.** Advantages and disadvantages of echocardiographical guidance during percutaneous interatrial shunt closure

Advantages
- Smaller risk of misplacement or suboptimal placement
- Smaller risk of missing additional shunts
- Immediate information about residual shunt
- No need for contrast medium injections
- Shared responsibility between interventional cardiologist and echocardiographer
Disadvantages
- Need for general anesthesia (perhaps even intubation) or at least deep sedation
- Risk of aspiration with esophageal intubation in supine position
- Increased cost for additional manpower or use of intracardiac (disposable) echocardiographic equipment
- Significantly prolonged procedure time and laboratory occupation

**TABLE 2.** Technique of percutaneous interatrial shunt closure with Amplatzer devices

- Outpatient procedure
- No echocardiographic guidance
- Local anesthesia at right groin
- Access through right femoral vein
- 0.035 inch (exchange) wire
- Multipurpose catheter to pass defect unless wire crosses spontaneously
- Balloon gauging (18 mm or 24 mm in small children, 34 mm in adults)
- 6-12 French sheath according to occluder size (9 French for PFO)
- Right atrial contrast medium injections (by hand, left anterior oblique and cranial view)
- Antibiotics (1 - 3 doses)
- Unrestricted physical activity after a few hours
- Acetylsalicylic acid 100 mg for 5 months
- Clopidogrel 75 mg for 1 month
- Prophylaxis against endocarditis (for 3 - 6 months)
- TEE at about 6 months (1 month after stopping platelet inhibitors)

device (25 mm Amplatzer Occluder) they can then move on to ASD closures, starting first with small defects (20 mm or smaller). Closure of larger defects (20 mm to 40 mm) should be reserved for subspecialized accomplished interventional cardiologists and percutaneous closure of even larger defects is currently not possible and may never be.

REFERENCES

1. Hagen PT, Scholz DG, Edwards WD. Incidence and size of patent foramen ovale during the first 10 decades of life: an autopsy study of 965 normal hearts. *Mayo Clin Proc* 1984; 59: 17-20.
2. Shah D, Azhar M, Oakley CM, Cleland JG, Nihoyannopoulos P. Natural history of secundum atrial septal defect in adults after medical or surgical treatment: a historical prospective study. *Br Heart J* 1994; 71:224-227; discussion 228.
3. King TD, Mills NL. Nonoperative closure of atrial septal defects. *Surgery* 1974; 75:383-388.
4. Bridges ND, Hellenbrand W, Latson L, Filiano J, Newburger JW, Lock JE. Transcatheter closure of patent foramen ovale after presumed paradoxical embolism. *Circulation* 1992; 86: 1902-1908.
5. Amin Z, Hijazi ZM, Bass JL, Cheatham JP, Hellenbrand WE, Kleinman CS. Erosion of Amplatzer septal occluder device after closure of secundum atrial septal defects: review of registry of complications and recommendations to minimize future risk. *Catheter Cardiovasc Interv* 2004; 63:496-502.
6. Meier B. Closure of patent foramen ovale: technique, pitfalls, complications, and follow up. *Heart* 2005; 91:444-8.
7. Meier B. Patent foramen ovale, guilty but only as a gang member and for a lesser crime. *J Am Coll Cardiol* 2006; 47:446-8.