

## Concomitant Radiofrequency – Microwave Ablation and Atrial Septal Defect Repair

M. Argiriou, MD, A. Krassas, MD, V. Panagiotakopoulos, MD,  
C. Spiliotopoulos, D. Asimomitis, MD, C. Charitos, MD

*2<sup>nd</sup> Cardiac Surgery Department  
of Evangelismos General Hospital  
Athens Greece*

---

### ABSTRACT

---

Atrial fibrillation (AF) is the most frequent form of atrial arrhythmias in adults with congenital heart disease. Some serious complications are related with the presence of AF after surgery. Because of the complexity and the risk of bleeding, the Maze III procedure has been largely replaced by alternative energy sources. A patient with multiple atrial septal defects (ASD) and AF underwent surgical closure with autologous pericardial patch and bipolar radiofrequency and microwave ablation.

---

### CASE REPORT

---

We report a case of successful left atrial radiofrequency bipolar - microwave ablation for chronic AF in a patient who had multiple ASDs. Preoperative echocardiogram showed that patient was in permanent AF (24 months) having a pulmonary to systemic flow ratio of 2.1:1. The left atrial dimensions was 50 mm, the right atrial area 48 x 67 mm<sup>2</sup> and the right ventricular dimension 34 mm. (Fig. 1) The operation was performed under cardiopulmonary bypass. Cold, antegrade blood cardioplegic solution was used. Ablation was performed in both the right and left atrium. Right atrial ablation lines included: (1) from the superior vena cava (SVC) cannulation to inferior vena cava (IVC) cannulation; (2) from the right appendage to the tricuspid valve annulus; (3) from the IVC to the coronary sinus; and (4) from coronary sinus to tricuspid valve annulus. In the left atrium, the ablation lines were as follows: (1) around the base of left appendage; (2) around the left and right pulmonary veins; (3) a line connecting the left appendage with the left superior pulmonary vein (4) a line connecting the two pulmonary veins circles; and (5) connecting the middle of the line to the posterior mitral valve annulus. Lesions (1), (2), (3) at the left atrium were created with isolator Synergy ablation clamp Atricure® which creates a uniform, column-shaped lesion, pulsating energy between the two pairs of electrodes. The result is a robust, high-definition lesion. The (4), (5) left atrium lesions which were created through the ASD and the right atrial lesions were created with microwave energy source using the Flex 4 microwave Guidant® (Fig. 2,3) The time of ablation was 18 min. Closure of ASDs with autologous pericardial patch was performed. (Fig. 4) There were no complications related to radiofrequency – microwave ablation and the patient discharged in sinus rhythm. The electrocardiogram at the 3 months follow-up was in sinus rhythm.

*Address for correspondence:*

2<sup>nd</sup> Cardiac Surgery Department  
of Evangelismos General Hospital  
Athens Greece  
E-mail: mihalisargiriou@ath.forthnet.gr

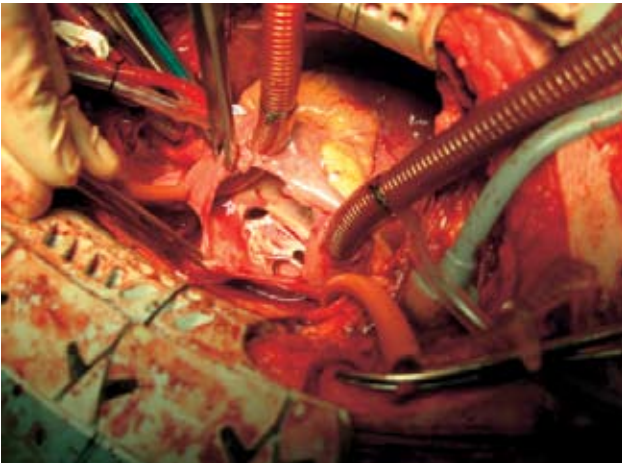


FIGURE 1.

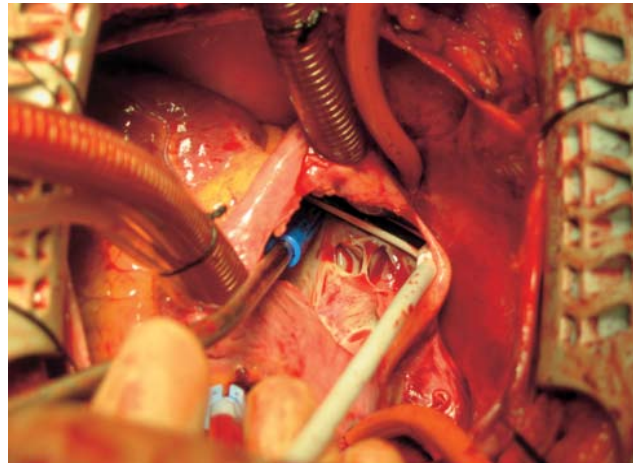


FIGURE 3.

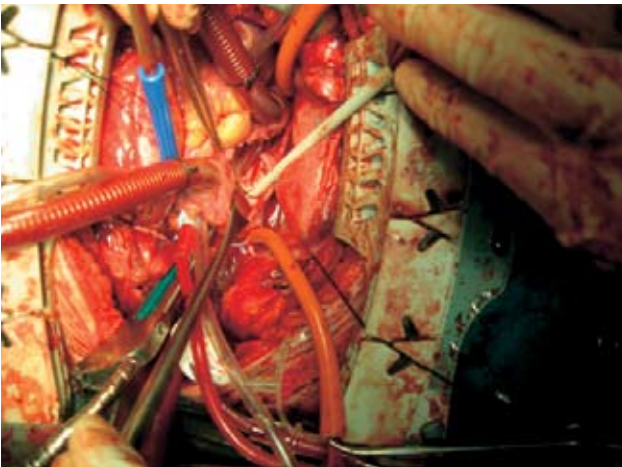


FIGURE 2.

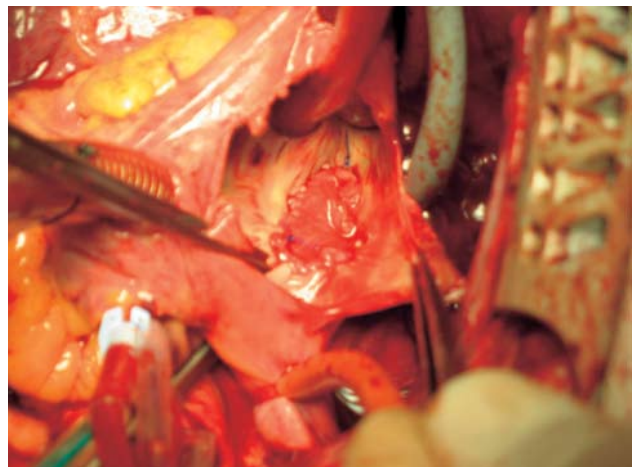


FIGURE 4.

---

DISCUSSION

---

Atrial fibrillation (AF) is the most frequent form of atrial arrhythmias in adults with congenital heart disease (CHD). The incidence of AF in adults with atrial septal defect (ASD) varies from 8% to 25%, and it increases with age. The occurrence of atrial arrhythmias does not decrease even when the defect is successfully surgically corrected<sup>1,2</sup> AF is found at late follow-up in approximately half of all adults who have had correction of ASD, even if it was not present preoperatively. These atrial tachycardias have a poor response to medication. These patients are thus exposed to the risks of stroke and chronic drug therapy even after a successful operation. Surgical correction of ASD leads to regression of the incidence of atrial flutter but not AF. Thus, surgical repair of ASD to abolish supraventricular tachyarrhythmias

in adults is warranted, but in patients with AF, it may have to be combined with a Maze operation.

**Conclusion.** The small added risk and the substantial benefit of eliminating AF suggest that this approach is warranted in selected adults with ASD. Bipolar radiofrequency and microwave ablation is an easy, effective, safe and economic concomitant operation to eliminate AF in adult patients with congenital heart defect and AF.

REFERENCES

1. Konstantinides S, Geibel A, Olschewski M, et al. A comparison of surgical and medical therapy for atrial septal defect in adults. *N Engl J Med* 1995; 333:469–473
2. Berger F, Vogel M, Kramer A, et al. Incidence of atrial flutter/fibrillation in adults with atrial septal defect before and after surgery. *Ann Thorac Surg* 1999; 68:75–78.