

ATHENS CARDIOLOGY UPDATE 2008

Treating Diffuse Three-vessel Coronary Artery Disease with Percutaneous Coronary Intervention

Ilias Karabinos, MD, Vassilis Spanos, MD

CASE REPORT

Euroclinic of Athens, Greece

We present a case of a 57-year-old man, with a history of heavy smoking, non-insulin dependent diabetes mellitus (NIDDM) and untreated hypercholesterolemia. He was complaining for typical angina on effort which started one month ago. He had a treadmill stress test which was terminated very early because of angina and ECG changes evident of myocardial ischemia.

Coronary angiogram showed diffuse disease of the right coronary artery (RCA) and 100% obstruction (Fig. 1), a non significant plaque at the distal part of left main coronary artery, diffuse disease in the left anterior descending (LAD) and left circumflex (LCx) (Fig. 2 & 3) with very significant and complex lesions at the proximal parts, and left ventricular ejection fraction impaired, estimated about 35%. We proposed that according to the evidence and the guidelines he should have surgery (CABG). Although we insisted on CABG, the patient rejected this treatment and asked for coronary angioplasty (PTCA).

We planned a two-stage procedure which included a first attempt to recanalize the RCA total occlusion and, if successful, then proceed with full revascularization, stenting only the ostia and the proximal parts of LAD and LCx. We also scheduled to use intravascular ultrasound (IVUS) in the left coronary artery in order to define vessel diameter, so that a stent of larger diameter could be implanted, and clarify about involvement of the left main.

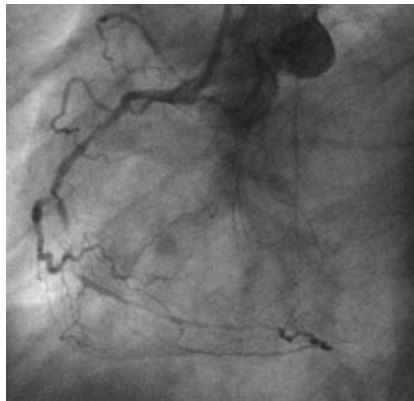


FIGURE 1.

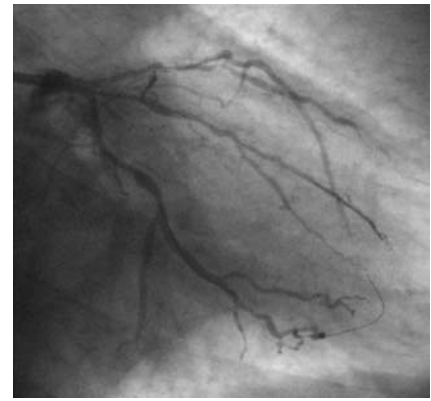


FIGURE 2.

Address for correspondence:
Ilias Karabinos
E-mail: iliaskk@in.gr

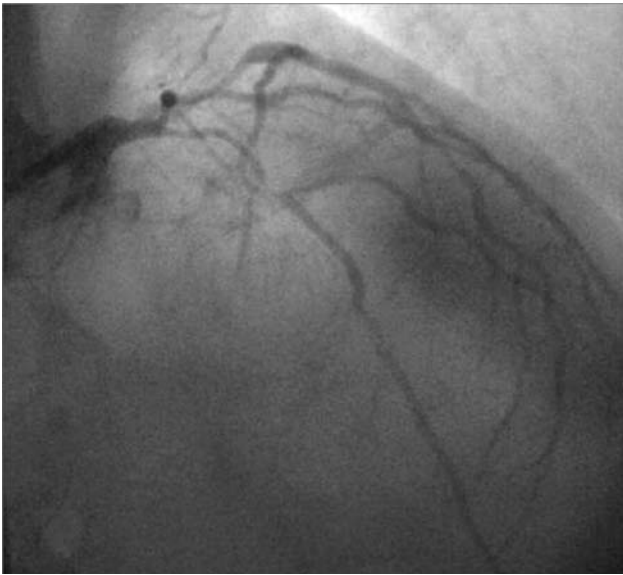


FIGURE 3.

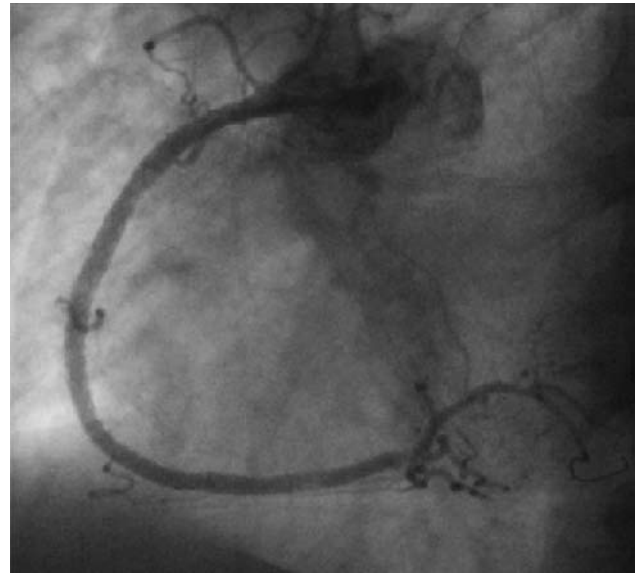


FIGURE 4.

The RCA was approached with a guiding catheter Judkins Right 3.5 6F. We used an over the wire balloon (Maverick 1.5X10mm) with a Whisper guidewire, crossing the total occlusion and reaching at the most distal part of the vessel. As the Maverick balloon could not be delivered distally, we exchanged for a monorail balloon Riujin 1.25x15 mm and we performed 3 inflations at 14 atm, thus restoring flow at the part of RCA after the total occlusion. We then used larger balloons (Sequent) 2x15mm and 2.5x10mm to prepare the vessel for total reconstruction. We decided to cover all the vessel from the ostium to the mid part and leaving the distal part before the crux diffusely diseased with good flow, and thus we implanted two overlapping stents Cypher Select plus 3x28 mm and 3x33 mm (at 14 atm) with a very good result. Subsequently, we changed strategy and decided to cover the distal part as well, but a Cypher Select plus 2.75x18 mm stent could not be delivered, although we post-dilated with a Maverick 3.5x18 mm balloon. Finally, we managed to deliver and implant 3 XScience stents overlapped (3x18 mm, 3x15 mm, 3x12 mm) at 14 atm, with a very good final result (Fig. 4). Tirofiban was administered during and after the procedure.

Five days later the patient came back for the second part of the staged procedure. We used an EBU 3.5 7F guiding catheter and the LAD, LCx and the intermediate vessel were all wired with Whisper guidewires. First, we used a Riujin 2x15 mm balloon, and then a Sequent 2.5x15 mm balloon to prepare the lesions of the LAD from the ostium to the mid part of the vessel resulting in good flow. An IVUS run in the LAD was then performed which demonstrated a medium size vessel (about 3 mm in diameter), with a lot of calcium and an atheromatic plaque at the distal part of the left main which did

not cause significant stenosis (area=8.6 mm²). A Taxus Liberte 2.75x28 mm stent was implanted in the mid part of the LAD, and another overlapping stent Taxus Liberte 3x32 mm could be delivered only after preparing the proximal LAD with a cutting balloon 3x10mm (at 12 atm) with a very good result. Then, we predilated the long lesion in the proximal LCx with a Sequent 2.5x10 mm and a Maverick 3X12 mm balloon, and we implanted two overlapping stents Taxus Liberte 2.75x16 mm and 3x16 mm (at 14 atm) with a very good result. The procedure ended with simple balloon angioplasty at the proximal lesion of the intermediate branch with a Maverick 3x12mm balloon with an acceptable result (Fig. 5 & 6). Tirofiban was infused during and after the procedure.

Totally, we treated 7 lesions in 3 vessels, using 9 DES and covering a total length of 198 mm. In one year follow up, the patient has not had any symptoms, has modified all risks factors (LDL=46 mg/dl, HbA1c=6.2%) and is in a very good physical condition. He has been submitted to dobutamine stress echo with contrast twice, reaching cardiac frequency 154/min which proved to be negative for myocardial ischemia.

DISCUSSION

The optimal therapeutic strategy for multi-vessel coronary artery disease still remains a controversial issue. Coronary artery bypass grafting (CABG) has long been the definitive, but aggressive therapeutic strategy for the treatment of patients with multi-vessel coronary artery disease. However, much progress in interventional cardiology has expanded its application from treating single, simple lesions to multiple

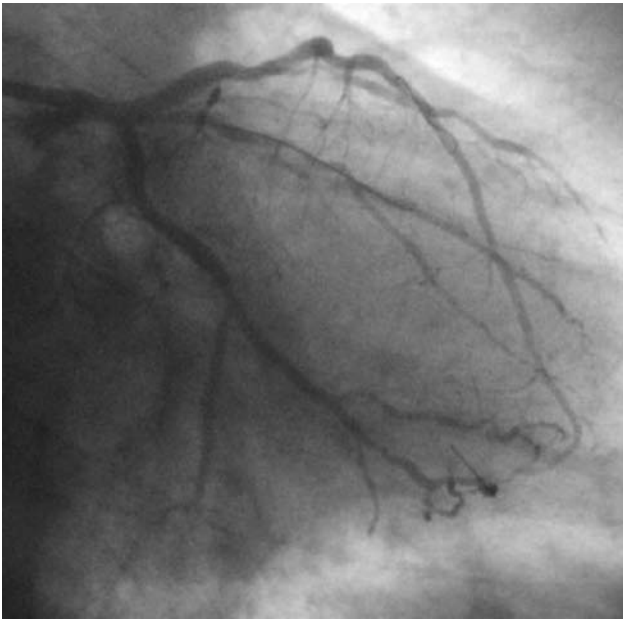


FIGURE 5.

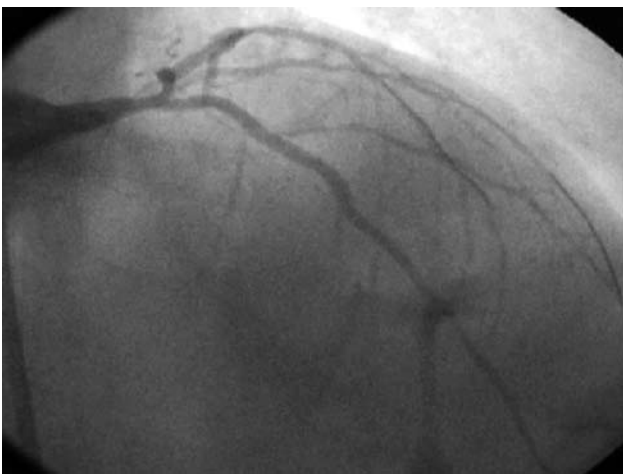

FIGURE 6.

and severely complex stenoses. Early trials [1-3] comparing percutaneous coronary intervention (PCI) with bare metal stent implantation and revascularization with CABG had raised an optimistic perspective regarding the efficacy of PCI in long-term results since no differences in terms of mortality and myocardial infarction had been identified. However, the CABG arm had been found superior to PCI regarding repeat revascularization and long-term relief from angina.

Four large multi-centre, randomized studies were conducted in the 1990s to compare bare metal stent implantation with CABG in patients with multivessel disease: AWESOME

[4], ERACI II [5,6], SOS [7] and ARTS [8,9]. The Angina With Extremely Serious Operative Mortality Evaluation (AWESOME) trial [4] was one of the first randomized, multi-center studies that did not identify statistical significant difference in the global survival or survival free of unstable angina among patients with multi-vessel disease treated with CABG or PCI with stent implantation in three years' follow up. Paradoxically, repeat revascularizations were observed to be generally greater in the surgical group than in the PCI group.

The ERACI II study (Argentine Randomised Study: Coronary angioplasty with stenting vs. coronary bypass surgery in multi-vessel disease) [5,6] included 450 patients and demonstrated better survival and freedom from myocardial infarction in the PCI arm compared with the surgical group during the first 30 days post-procedurally, when more patients died in the surgical group, but disappeared after one month. CABG in-hospital mortality in the ERACI II study was higher than in other trials, but was mainly observed in patients with severe unstable angina. Moreover, revascularization procedures and major adverse cardiovascular events were significantly less in the group of CABG.

The SoS (Stent or Surgery) trial [7] was conducted in 53 centers in Europe and Canada and 988 patients were randomized. The incidence of death or non-fatal Q-wave myocardial infarction was similar in both groups but survival was significantly lower in the PCI arm which was however mainly attributed to the increased rate of cancer-related deaths.

The Arterial Revascularisation Therapies Study (ARTS) [8,9] was designed to compare CABG and stenting in patients with multi-vessel disease. In total, 1205 patients from 67 participating centers were randomized to either stent implantation or CABG. Overall survival, stroke, or myocardial infarction was not significantly different between PCI and CABG groups in 1 and 5 years follow-up. However, repeat revascularization was found significantly higher in the PCI group than in the CABG group.

A recent meta-analysis [10] of the these four studies confirmed that patients with multi-vessel disease undergoing surgical revascularization or stent implantation were protected against death, myocardial infarction, or stroke to a similar degree. In contrast, repeat revascularization procedures were higher in the PCI group.

Drug-eluting stents (DES) seem to overcome the disadvantages that restrict the unlimited use of bare metal stents. Non-randomized studies and registries have shown promising results regarding high-risk populations with complex lesions [11,12]. However, concerns have been raised recently regarding the long-term safety of DES, as a consequence of the reported potentially increased risk of late thrombosis [13,14]. Therefore, revascularization with DES should be compared with CABG in new large-scale, randomized trials which will enroll high risk patients.

ARTS II (Arterial Revascularisation Therapies Study

II) [15] compared the effectiveness of sirolimus-eluting stent implantation with the historical two arms of ARTS. ARTS II enrolled 607 patients (53.5% with 3-vessel disease) from 45 centers. The composite major adverse cardiac and cardiovascular events at one year follow up were low (10.5%) and were comparable as the historical surgical arm of ARTS. Although the re-intervention rates in the drug-eluting stents group were still higher than those of the CABG group, this was counter-balanced by a higher incidence of death / stroke and myocardial infarction. Moreover, diabetic patients in the DES group had a twofold greater need for repeat revascularization in the first year as compared to non-diabetic patients, although having lower event rates than those in the bare metal group.

The SYNTAX trial (SYNergy between percutaneous coronary intervention with TAXus and cardiac surgery) [16] is a multi-center, randomized study, designed to evaluate the optimum revascularization treatment for patients with *de novo* 3-vessel disease and/or left main disease (either isolated or with 1-, 2-, or 3-vessel disease). In this study patients are randomized to either PCI with paclitaxel-eluting stents or surgery, only if PCI and CABG can achieve comparable revascularization as judged by a local heart team consisting of an interventional cardiologist, cardiothoracic surgeon and study coordinator. The excluded patients are enrolled and follow-up in the Registry Arm. A total of 1500 patients have been randomized from 90 centers in Europe and in the USA. The primary endpoint is freedom from major adverse cardiac and cerebral events at one year. The CABG registry will determine the high-risk subsets that are not suitable for PCI, whereas the PCI registry may define the population for which CABG is inappropriate.

The FREEDOM multi-centre trial will randomize 2400 diabetic patients with 2- or 3-vessel disease to either surgical or percutaneous revascularization with DES. The study will be conducted in North America and Europe and the primary endpoint is mortality at 5 years.

The CARDia (Coronary Artery Revascularisation in Diabetes) trial [17] is conducted in the UK and Ireland and will randomize 600 diabetic patients with either complex one-vessel disease or multi-vessel disease to CABG or PCI. The primary endpoint is the composite incidence of death, non-fatal myocardial infarction or non-fatal stroke at one year.

The promising results demonstrated in small-scale studies and registries suggest that DES may abolish the limitations encountered with bare metal stent implantation. The results of SYNTAX, FREEDOM and CARDia are expected with great interest and will probably expand the indications for PCI in more complex and high-risk lesions. According to the current guidelines, patients with three-vessel disease with impaired ejection fraction and presence of diabetes mellitus must be treated with CABG. However, there are exceptions, such as diffuse disease, contra-indications to CABG and patient's wish, where PTCA is a very good alternative. In 3-vessel dif-

fuse disease, CABG is not superior to PTCA with DES. In order to avoid excess length of DES, we think that it is wise to open the proximal-mid parts of all three vessels and leave the distal parts as they are if the flow is TIMI 3, just as the surgeon would do so for sure.

REFERENCES

1. Coronary angioplasty versus coronary artery bypass surgery: the Randomized Intervention Treatment of Angina (RITA) trial. *Lancet* 1993; 341: 573-580.
2. CABRI Trial Participants: First-year results of CABRI (Coronary Angioplasty versus Bypass Revascularisation Investigation). *Lancet* 1995; 346: 1179-1184.
3. The BARI Investigators: Comparison of coronary bypass surgery with angioplasty in patients with multivessel disease. *N Engl J Med* 1996; 335: 217-225.
4. Morrison DA, Sethi G, Sacks J, et al: Percutaneous coronary intervention versus coronary artery bypass graft surgery for patients with medically refractory myocardial ischemia and risk factors for adverse outcomes with bypass: a multicenter, randomized trial. Investigators of the AWESOME trial. *J Am Coll Cardiol* 2001; 38: 143-149.
5. Rodriguez A, Bernardi V, Navia J, et al: Argentine Randomized Study: Coronary angioplasty with stenting versus coronary bypass surgery in patients with multiple-vessel disease (ERACI II): 30-day and one-year follow-up results. ERACI II Investigators. *J Am Coll Cardiol* 2001; 37: 51-58.
6. Rodriguez AE, Baldi J, Fernandez Pereira C, et al: Five-year follow-up of the ERACI II. *J Am Coll Cardiol* 2005; 46: 582-588.
7. The SoS Investigators: Coronary artery bypass surgery versus percutaneous coronary intervention with stent implantation in patients with multivessel coronary artery disease (the Stent or Surgery trial): a randomised controlled trial. *Lancet* 2002; 360:965-970.
8. Serruys PW, Unger F, van Hout BA, et al: The ARTS study (Arterial Revascularization Therapies Study). *Semin Interv Cardiol* 1999; 4: 209-219.
9. Serruys PW, Ong AT, van Herwerden LA, et al: Five-year outcomes after coronary stenting versus bypass surgery for the treatment of multivessel disease: the final analysis of the Arterial Revascularization Therapies Study (ARTS) randomized trial. *J Am Coll Cardiol* 2005; 46: 575-581.
10. Mercado N, Wijns W, Serruys PW, et al: One-year outcomes of coronary artery bypass graft surgery versus percutaneous coronary intervention with multiple stenting for multisystem disease: a meta-analysis of individual patient data from randomized clinical trials. *J Thorac Cardiovasc Surg* 2005; 130: 512-519.
11. Chieffo A, Stankovic G, Bonizzoni E, et al: Early and midterm results of drug-eluting stent implantation in unprotected left main. *Circulation* 2005; 111: 791-795.
12. Korovesis S, Karvouni E, Giazitzoglou E, et al: Drug-eluting stents: immediate and long-term results. *Hellenic J Cardiol*

- 2005; 46: 330-335.
13. Iakovou I, Schmidt T, Bonizzoni E, et al: Incidence, predictors, and outcome of thrombosis after successful implantation of drug-eluting stents. *JAMA* 2005; 293: 2126-2130.
 14. Ong AT, Hoyer A, Aoki J, et al: Thirty-day incidence and six month clinical outcome of thrombotic stent occlusion after bare-metal, sirolimus, or paclitaxel stent implantation. *J Am Coll Cardiol* 2005; 45: 947-953.
 15. Serruys P, Ong AT, Morice MC, et al: Arterial Revascularisation Therapies Study Part II – Sirolimus-eluting stents for the treatment of patients with multivessel de novo coronary artery lesions. *EuroIntervention* 2005; 2: 147
 16. Ong AT, Serruys PW, Mohr FW, et al: The SYNergy between percutaneous coronary intervention with TAXus and cardiac surgery (SYNTAX) study: design, rationale, and run-in phase. *Am Heart J* 2006; 151: 1194-1204.
 17. Kapur A, Malik IS, Bagger JP, et al: The Coronary Artery Revascularisation in Diabetes (CARDia) trial: background, aims, and design. *Am Heart J* 2005; 149: 13-19.