

ATHENS CARDIOLOGY UPDATE 2008

SPECT/CT Fusion Imaging Integrating Anatomy and Perfusion of the Heart

Ioannis V. Vassiliadis, MD, FESC, FACC

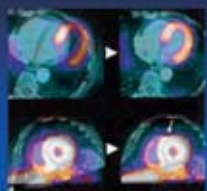



*Consultant Cardiologist, Euroclinic Hospital, Athens
Head Cardiovascular Imaging, Euromedica- Encephalos Center, Athens*

In the rapidly changing world of medicine, boundaries between specialties are constantly being challenged. Fused and hybrid imaging with integration of single photon emission computed tomography (SPECT) and computed tomography (CT)(SPECT/CT) and positron emission tomography (PET) and CT (PET/CT), represent an area of very rapid growth with significant implications for the medical profession. SPECT and PET scanners have now been linked to computer topographic (CT) scanners, which are digital radiological systems which acquire data in the axial plane, producing images of the heart, as well as other internal organs, of high spatial and contrast resolution.

The combination of SPECT or PET and CT for image fusion, either as a single unit or as a software-based integration of SPECT or PET myocardial perfusion imaging (MPI) and CT angiography (CTA) data sets from standalone scanners, can provide us with a simultaneous noninvasive assessment of coronary anatomy and myocardial perfusion.

The benefits of such fusion imaging lie in the greater diagnostic confidence for the evaluation and the appropriate management of coronary artery disease (CAD). Not

SPECT /CT Fusion

- SPECT/CT Co registration
Alignment of SPECT and CT images on axial, sagittal, coronal images planes. Rotation correction along the heart's LAX using the transition of left to right ventricle
- Definition of the epicardium
Determination of LV epicardium contours on CT images. Semi automatically with manual adjustments. Projection of SPECT information onto LV epicardium (same window presets as in SPECT images)
- Coronary tree segmentation
Segmentation of coronary artery vasculature with automatic vessel tracking
- 3D VR Fusion: Combination of LV epicardium and coronary tree . Fading of RV structure for visualization of septal wall

GE Card IQ Fusion software. Gaemperli EJNM 2007

Address for correspondence:
e-mail: vassiliadis@hellasnet.gr

all coronary artery stenoses are flow limiting, and SPECT or PET stress perfusion imaging complements the anatomical CT data by providing functional information on the hemodynamic significance of such stenoses, thus allowing more appropriate selection of patients who may benefit from revascularization procedures.

Moreover with this combined approach there are additional advantages such as the calcium scoring that has incremental prognostic value, the attenuation correction that limits false positive perfusion results and the future perspective in identifying the vulnerable plaque.

As myocardial perfusion imaging by SPECT does not require an on-site cyclotron or an expensive rubidium generator, integration of high-end multi-slice establish a more important role in cardiac imaging.

We are currently evaluating the potential of a software fusion of SPECT/CT co-registration. The major challenge for future developments will be to identify which patients will benefit from a combined hybrid approach as opposed to

a single-modality approach with stepped testing.

REFERENCES

1. Slomka PJ. Software approach to merging molecular with anatomic information. *J Nucl Med* 2004;45 Suppl 1:36S45S.
2. Gaemperli O, Schepis T, Valenta I, et al. Cardiac image fusion from stand-alone SPECT and CT: clinical experience. *J Nucl Med* 2007;48(5):696-703.
3. Gaemperli O, Schepis T, Koepfli P, et al. Accuracy of 64-slice CT angiography for the detection of functionally relevant coronary stenoses as assessed with myocardial perfusion SPECT. *Eur J Nucl Med Mol Imaging* 2007;34:1162-71.
4. Mahmarijan JJ. Hybrid SPECT-CT: integration of CT coronary artery calcium scoring and angiography with myocardial perfusion. *Curr Cardiol Rep* 2007;9:129-35.
5. Bax JJ, Beanlands RS, Klocke FJ, et al. Diagnostic and clinical perspectives of fusion imaging in cardiology: is the total greater than the sum of its parts? *Heart* 2007;93:16-22.